

23390930

Request # 23390930

SEP 26, 2007

Email (PDF) To: Scal.Rvsd-Medical-Library@kp.org

Kaiser Permanente Riverside
Health Sciences Library
10800 Magnolia Avenue
Riverside, CA 92505

RUSH DOCLINE: Journal Copy EFTS Participant

Title: Academic radiology
Title Abbrev: Acad Radiol
Citation: 2007 Aug;14(8):945-50
Article: Detection of ductal carcinoma in situ with mammogr
Author: Brem R;Fishman M;Rapelyea J
NLM Unique ID: 9440159 Verify: PubMed
PubMed UI: 17659240
ISSN: 1076-6332 (Print)
Publisher: Association Of University Radiologists, Reston Va
Copyright: Copyright Compliance Guidelines
Authorization: Maria Ramirez
Need By: N/A
Maximum Cost: **\$6.00**
Patron Name: Dr. Tadwalkar 4736
Referral Reason: Not owned (title)
Library Groups: FreeShare,IEMLC,KPLS,MLGSCA
Phone: 1.951.353-3659
Fax: 1.951.353-3262
Alternate Delivery: Web(PDF)
Comments: **Thank You (Can only pay with MLGSCA coupons or EFTS)**
Routing Reason: Routed to TXUBGH in Serial Routing - cell 4
Received: Sep 27, 2007 (07:58 AM EST)
Lender: BROOKE ARMY MEDICAL CENTER/ FT SAM HOUSTON/ TX USA (TXUBGH)

This material may be protected by copyright law (TITLE 17,U.S. CODE)

Bill to: CAUKAB

Kaiser Permanente Riverside
Health Sciences Library
10800 Magnolia Avenue
Riverside, CA 92505

Detection of Ductal Carcinoma in Situ with Mammography, Breast Specific Gamma Imaging, and Magnetic Resonance Imaging: A Comparative Study¹

Rachel F. Brem, MD, Michael Fishman, Jocelyn A. Rapelyea, MD

Rationale and Objectives. To evaluate the sensitivity of high-resolution breast-specific gamma imaging (BSGI) for the detection of ductal carcinoma in situ (DCIS) based on histopathology and to compare the sensitivity of BSGI with mammography and magnetic resonance imaging (MRI) for the detection of DCIS.

Materials and Methods. Twenty women, mean 55 years (range 34–76 years), with 22 biopsy-proven DCIS were retrospectively reviewed. After injection of 25–30 mCi (925–1,110 MBq) technetium 99m-sestamibi, patients had BSGI with a high-resolution, small-field-of-view gamma camera in craniocaudal and mediolateral oblique projections. BSGI studies were prospectively classified according to focal radiotracer uptake using a 1 to 5 scale, as normal 1), with no focal or diffuse uptake; benign 2), with minimal patchy uptake; probably benign 3), with scattered patchy uptake; probably abnormal 4), with mild focal radiotracer uptake; and abnormal 5), with marked focal radiotracer uptake. Imaging findings were compared to findings at biopsy or surgical excision. The sensitivity of BSGI, mammography, and when performed, MRI were determined for the detection of DCIS. Breast MRI was performed on seven patients with eight biopsy-proven foci. The sensitivities were compared using a two-tailed *t*-test and confidence intervals were determined.

Results. Pathologic tumor size of the DCIS ranged from 2 to 21 mm (mean 9.9 mm). Of 22 cases of biopsy-proven DCIS in 20 women, 91% were detected with BSGI, 82% were detected with mammography, and 88% were detected with magnetic resonance imaging. BSGI had the highest sensitivity for the detection of DCIS, although this small sample size did not demonstrate a statistically significant difference. Two cases of DCIS (9%) were diagnosed only after BSGI demonstrated an occult focus of radiotracer uptake in the contralateral breast, previously undetected by mammography. There were two false-negative BSGI studies.

Conclusions. BSGI has higher sensitivity for the detection of DCIS than mammography or MRI and can reliably detect small, subcentimeter lesions.

Key Words. Breast cancer; molecular imaging; breast biopsy; nuclear medicine imaging.

© AUR, 2007

Acad Radiol 2007; 14:945–950

¹ From Breast Imaging and Intervention (R.F.B., J.A.R.) and the Department of Radiology (M.F.), The George Washington University, 2150 Pennsylvania Avenue NW, Washington, DC 20037. Received February 15, 2007; accepted April 8, 2007. Bristol-Myers Squibb (Billerica, MA) provided grant support for the study and offered the radiotracer as an in-kind donation. No authors are employed by Bristol-Myers Squibb or Dilon Technologies. R.F.B. has stock options in Dilon Technologies and recently joined the Board of Managers and has been on the speaker's bureau for Bristol-Myers Squibb (previously DuPont Pharmaceuticals). No other authors have any other relationship with Bristol-Myers Squibb or Dilon Technologies. The data reported in this study, as well as the submission of this manuscript, always remained in sole possession of the authors. Address correspondence to: R.F.B. e-mail: rrbrem@mfa.gwu.edu

© AUR, 2007

doi:10.1016/j.acra.2007.04.004

Ductal carcinoma in situ (DCIS) occurs in approximately 28% or more than 58,000 cases of breast cancer in the United States (1). Mammography, the only accepted screening tool for breast cancer, detects the majority of clinically occult DCIS as microcalcifications, the hallmark mammographic finding of DCIS (2). Yet, the diagnosis of DCIS remains difficult because mammography is unreliable in predicting the histology and extent of DCIS (2–5).

Breast MRI has been shown to have a sensitivity of 73%–89% for DCIS, but a limited specificity (58%–89%) and variable positive predictive value (25%–84%) (1–3,5). As with mammography, small foci of DCIS are difficult to detect on magnetic resonance imaging (MRI), particularly lesions smaller than 5 mm (6,8). In addition, MRI may overestimate DCIS extent in as many as 50% of cases and often cannot distinguish benign from malignant lesions, high-grade from low-grade DCIS, or detect an invasive component concurrent with the DCIS (3–5). As a result, MRI remains a secondary study with limitations in DCIS detection and evaluation.

Breast specific gamma imaging (BSGI), nuclear medicine imaging of the breast using a high-resolution gamma camera, is an increasingly used adjunct imaging modality for the diagnosis of breast cancer. Recent studies have shown the potential of BSGI as a valuable complement to mammography in detecting breast cancer (9–12).

The purpose of this study is to determine the sensitivity of BSGI, mammography, and MRI for the detection of DCIS and to compare the sensitivity of BSGI with mammography and MRI.⁴

MATERIALS AND METHODS

Between July 2001 and July 2006, 290 underwent clinically indicated BSGI for equivocal or suspicious mammographic findings. Twenty nonpregnant women, mean 55 years (range 34–76 years), were diagnosed with pure DCIS after definitive biopsy or at surgical excision. Retrospective review of these 20 women was performed and constitutes the study population.

BSGI was performed before biopsy to further evaluate an indeterminate breast finding and after biopsy demonstrating DCIS to evaluate for occult foci as well as to determine extent of disease for surgical planning. Pathologic results were correlated with mammography, BSGI, and MRI when deemed indicated for the clinical care of the patient. Pathology reports were retrospectively re-

viewed for tumor size and nuclear grade. The highest nuclear grade reported on biopsy or surgical excision was included in the analysis.

BSGI was performed after injection of 25–30 mCi (925–1,110 MBq) technetium 99m-sestamibi in an antecubital vein. Patients were imaged with a high-resolution, small-field-of-view breast-specific gamma camera (Dilon 6800; Dilon Technologies, Newport News, VA). Cranio-caudal and mediolateral oblique projections were obtained, as were additional projections as clinically indicated. The acquisition time for each image was approximately 10 minutes, with a total imaging time of approximately 40 minutes per study.

BSGI studies were prospectively read by two radiologists with expertise in BSGI interpretation. Correlation with mammography and MRI was made when available. BSGI was classified according to focal radiotracer uptake using a 1 to 5 scale, as 1) normal with no focal or diffuse uptake; 2) benign with minimal patchy uptake; 3) probably benign with scattered patchy uptake; 4) probably abnormal with mild focal radiotracer uptake; and 5) abnormal with marked focal radiotracer uptake.

Mammography was performed (GE DMR, Milwaukee, WI) initially in the cranio-caudal and mediolateral oblique projections. Additional views were obtained as deemed clinically indicated by the interpreting radiologist. Results were based on mammographic findings in the clinical report obtained from the patient record.

MRI was performed using a GE 1.5-T system (GE Healthcare, Milwaukee, WI) using a dedicated breast coil. An initial three-dimensional localizing sequence was performed, followed by sagittal T1 with fat saturation (repetition time 525 milliseconds/echo time 12–24 milliseconds), T2 with fat saturation (6,000/85), and axial T2 (6,000/85) fat-saturated sequences. After administration of 33 mL of gadopentetate-dimeglumine (Magnevist, Berlex, Germany) three-dimensional volumetric dynamic images were obtained at 70-second intervals for a total of five cycles followed by a sagittal T1 (6.3/2.9–12) fat-saturated postcontrast sequence. MRI results were based on the generated report in the patient record. MRI and BSGI examinations were performed within 2 weeks.

The sensitivity of BSGI, mammography, and, when performed, MRI were determined for the detection of DCIS and compared using a two-tailed *t*-test. Statistical significance was defined as being within the 95% confidence intervals.

Institutional review board approval and informed consent were obtained. The study was Health Insurance Portability and Accountability Act-compliant.

RESULTS

Twenty women with 22 biopsy-proven DCIS lesions were included. DCIS was bilateral in two women, in the right breast in 8 women and in the left breast in 10 women. Pathologic tumor size was available in nine cases, ranging from 2 to 21 mm (mean 9.9 mm). Four DCIS lesions were less than 5 mm in size, two 6–10 mm in size, two 11–20 mm in size, and one greater than 20 mm in size. Of the remaining tumors, 12 were extensive within the breast and size could not be determined; the final DCIS lesions were diagnosed at 9-gauge vacuum-assisted core biopsy (ATEC, Suros Surgical, Cincinnati, OH) with no residual disease at surgical excision. Nuclear grading was available for all DCIS lesions and classified as high ($n = 11$), intermediate ($n = 9$), and low ($n = 2$). Comedonecrosis was present in 10 DCIS, all intermediate- or high-grade tumors.

Clinically, three patients (15%) presented with unilateral bloody nipple discharge, one (5%) with a palpable mass, and one (5%) with a history of contralateral DCIS 5 years previously and underwent BSGI for high-risk surveillance. The remaining 15 patients (75%) presented with an abnormal mammogram. In 16 women, DCIS was diagnosed using minimally invasive biopsy. BSGI was performed after the diagnosis to evaluate for multifocality, bilaterality, and extent of disease and to assist in surgical planning. The remaining four women had an abnormal mammogram and BSGI before biopsy to further evaluate an indeterminate mammographic finding. Two cases of DCIS (9%) were diagnosed only after BSGI demonstrated an occult focus of radiotracer uptake in the contralateral breast, previously undetected by mammography (Fig 1).

BSGI versus Mammography

All patients were evaluated with mammography before BSGI. Of the 22 cases of biopsy-proven DCIS, 18 were detected with mammography for a sensitivity of 82%. The mammographic findings were calcifications ($n = 16$), calcifications with spiculated mass ($n = 1$), and mass ($n = 1$). Mammography was negative in four patients with DCIS, including the two patients with occult, bilateral disease diagnosed only after abnormal BSGI.

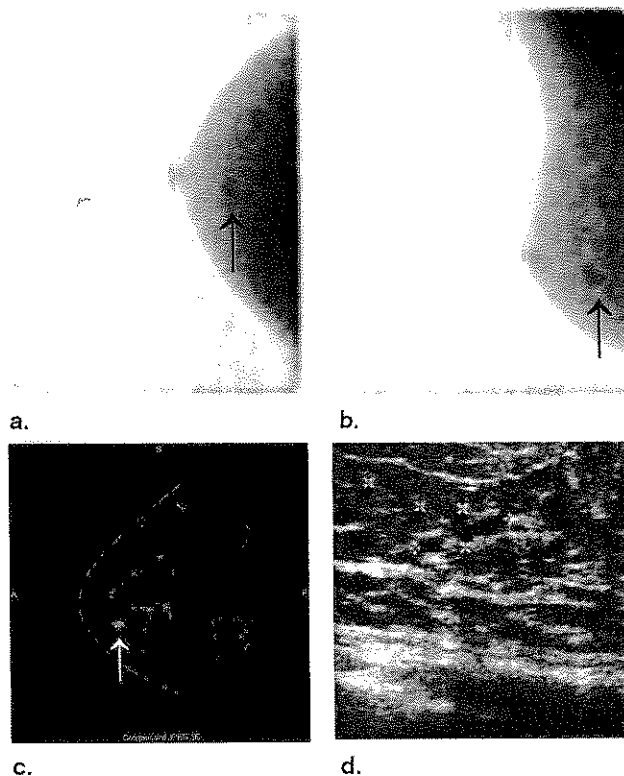


Figure 1. High-resolution breast-specific gamma imaging, magnetic resonance imaging (MRI), and ultrasound in a 59-year-old patient with known ductal carcinoma in situ (DCIS) in the right breast. Breast-specific gamma imaging (BSGI) of the left breast: (a) craniocaudal and (b) left mediolateral oblique views demonstrate subtle focus uptake in the lower left breast (black arrows). (c) Sagittal T1 fat-suppressed postcontrast MRI of the left breast demonstrated a 7-mm enhancing lesion with linear enhancement (white arrow). (d) Second look ultrasound of the left breast demonstrated a vague hypoechoic area at the 6:30 position (markers). A 4-mm focus of low-grade DCIS was found on excisional biopsy. The left breast DCIS was newly detected on BSGI and was a contralateral occult focus in a patient with known right DCIS.

Both cancers measured 4 mm at surgical excision. The remaining two patients with false-negative mammograms and true-positive BSGI presented with bloody nipple discharge ($n = 1$) and a palpable mass visualized with ultrasound ($n = 1$).

In 20 women with 22 cases of DCIS, the sensitivity of BSGI was 91%. Figure 2 is an example of a true-positive BSGI in DCIS. There were two false-negative BSGI studies. In both, mammography demonstrated an indeterminate cluster of microcalcifications and biopsy with stereotactic vacuum assisted biopsy demonstrated DCIS. At surgical excision, one patient had no residual DCIS and one had extensive DCIS with no single focus greater than 10 mm. These patients were not evaluated with MRI.

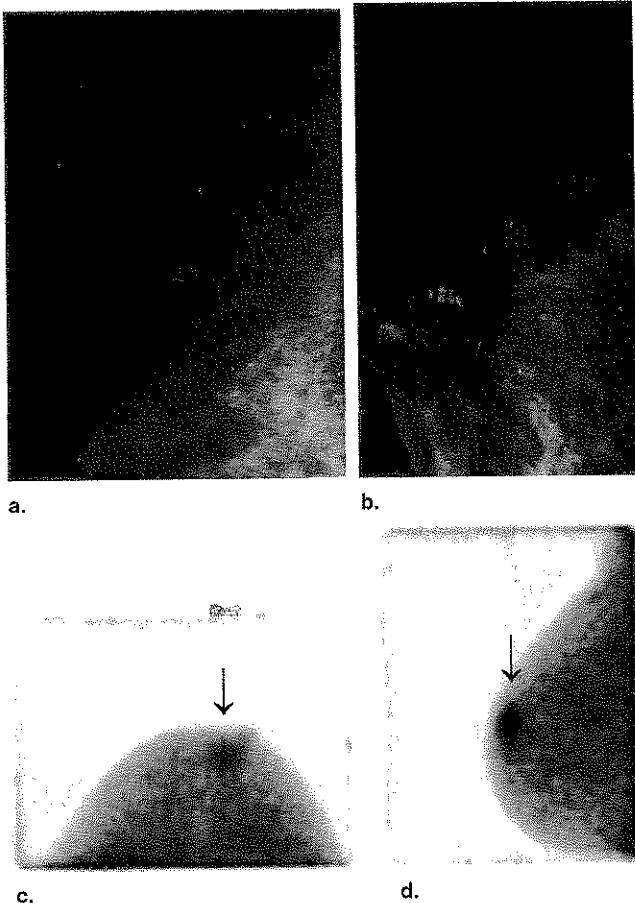


Figure 2. Mammography and high-resolution breast specific gamma imaging in a 69-year-old patient with ductal carcinoma in situ of the right breast. (a) Right craniocaudal and (b) right mediolateral oblique magnification mammography views demonstrate a cluster of indeterminate microcalcifications in the subareolar right breast. Breast-specific gamma imaging (c) right craniocaudal and (d) right mediolateral oblique views demonstrated focal increased radiotracer uptake in the upper retroareolar region (black arrows). Pathology demonstrated a 6-mm focus of high-grade DCIS.

BSGI versus MRI

Breast MRI was performed in seven patients with eight biopsy-proven foci of DCIS and demonstrated seven areas of abnormal enhancement (sensitivity 88%). This included an occult contralateral DCIS in one patient with bilateral disease, detected initially by BSGI. There was one false-negative MRI examination, which at surgical excision demonstrated a 4-mm DCIS. This false-negative MRI was positive with BSGI imaging.

Overall, the sensitivity for DCIS was 82% with mammography, 91% with BSGI, and 88% with MRI. Statistical analysis performed using a two-tailed *t*-test does not demonstrate a statistically significant difference in detec-

Table 1
Two-Tailed *t*-test Evaluating Sensitivity of Breast-Specific Gamma Imaging (BSGI) to Mammography and Magnetic Resonance Imaging (MRI)

Contrast	Value of Contrast	Standard Error	<i>t</i>	df	<i>P</i> Value
(BSGI to mammography)	0.09	0.105	0.864	49	.392
(BSGI to MRI)	0.03	0.144	0.237	49	.814

Table 2
Confidence Intervals

Imaging Modality	95% Confidence Intervals
Breast-specific gamma imaging (n = 22)	0.78–1.04
Mammography (n = 22)	0.64–0.99
Magnetic resonance imaging (n = 8)	0.58–1.17

tion rates of DCIS between the three imaging modalities (Table 1, Table 2).

DISCUSSION

Screening and diagnostic mammography currently are the gold standard for detecting DCIS despite a variable reported sensitivity of 22%–86% (2–5). Microcalcifications are the most common finding, detected in 73%–98% of DCIS, and typically evaluated by vacuum-assisted biopsy using stereotactic guidance (5). Because of the reported low specificity and positive predictive value of mammography, there is a need for adjunct imaging modalities to complement mammography in detection and evaluation of DCIS, particularly in assessing additional occult foci and tumor extent.

Previous studies on scintimammography have reported sensitivities for invasive cancer of 56%–100%, and for DCIS of 46%–100%, although the size of DCIS lesions was not reported in most studies (13,22,23).

A standard gamma camera has intrinsic resolution limitations and cannot reliably detect subcentimeter cancers, which account for nearly one-third of all breast cancers detected by screening mammogram (9–12,14). BSGI uses a high-resolution, small-field-of-view breast-specific gamma camera with proven results in reliably detecting small, subcentimeter breast cancer (11,12). In contrast to the anatomic studies of mammography and ultrasound, BSGI offers the advantage of being a physiologic or func-

tional study, with sensitivity unaffected by dense breast tissue, implants, or architectural distortion after surgery or radiation (10,13–15). False-positives can occur with BSGI, the most common being fibrocystic disease, fibroadenoma, papillomatosis, atypical ductal hyperplasia, and fat necrosis (13).

Despite reports of the sensitivity in detecting breast cancer using scintimammography with a traditional gamma camera and BSGI with a high-resolution breast-specific gamma camera, few studies directly examine the sensitivity of DCIS (13,14,16–20). Khalkhali et al reported eight cases of DCIS, all detected by scintimammography for a sensitivity of 100%, although the size of the DCIS lesions is not reported and five of the eight DCIS lesions in this study were palpable (21). In a multicenter trial to evaluate the diagnostic accuracy of scintimammography, Khalkhali et al reported a sensitivity of 46% for the detection of DCIS (22). Of the DCIS detected, sensitivity favored palpable (57%) versus nonpalpable (39%) tumors, although the high prevalence of palpable DCIS in this study does not accurately reflect typical clinical practice and is skewed toward larger, palpable DCIS (22). Papanitiou et al reported a sensitivity of 75% in the detection of pure DCIS using a different radiotracer, 99m technetium (V) DMSA, in scintimammographic imaging (23). The false-negative DCIS on scintimammography measured 8 mm, and the mean DCIS size was 33 mm (range 8–50 mm), again favoring scintimammographic detection of larger or palpable DCIS (23).

The intrinsic resolution limitation using standard gamma cameras is, at least, in part responsible for the lower sensitivity for detecting DCIS than reported in our study. In a recent report using a high-resolution, breast-specific gamma camera, the sensitivity of four cases of DCIS was 100% with no subcentimeter lesions included in that report (10). Three of these DCIS were detected only with BSGI, not visible with mammography (10). Our findings concur with those previously reported demonstrating 100% sensitivity of BSGI for the detection of DCIS greater than 1 cm (10). In our study, the two false-negative DCIS lesions at BSGI were a DCIS diagnosed with stereotactic vacuum assisted biopsy with no residual disease at surgical excision, and an extensive DCIS throughout the breast initially diagnosed with stereotactic vacuum-assisted biopsy with no single focus greater than 10 mm.

Statistical analysis using a two-tailed *t*-test did not demonstrate a statistically significant difference in DCIS detection between BSGI and mammography or MRI.

However, the confidence intervals demonstrate a trend toward improved detection using BSGI. It is possible that with larger sample sizes in future studies, the differential ability of mammography, MRI, and BSGI may be different.

Studies of MRI detection of breast cancer report high sensitivity for invasive cancer (97%–100%), but few studies specifically examine the detection of DCIS, with early studies reporting sensitivity ranging from 40% to 100% (3,24). Recent studies reported MRI sensitivity for the detection of DCIS ranging from 73% to 97%, similar to our reported sensitivity of 88% for DCIS (3–7). The lower specificity of MRI in detecting DCIS (58%–89%) continues to limit its utility (3,6,22). Additional studies are needed to further evaluate and compare the sensitivity and specificity of MRI and BSGI in the detection of DCIS.

In this study, BSGI accurately detected all four DCIS ≤ 5 mm (100%) and all six DCIS ≤ 10 mm (100%) with measurable residual disease at surgical excision. Overall, BSGI demonstrated 91% sensitivity for DCIS, including extensive disease with no reported size and the single case diagnosed by vacuum-assisted core biopsy with no residual disease at surgical excision. This high sensitivity for small DCIS strengthens the utility of BSGI as an adjunct imaging modality in detecting small, noninvasive carcinoma. Furthermore, our study demonstrates the reliable detection of small subcentimeter DCIS with BSGI. Future studies must address other characteristics of DCIS and the impact on radiotracer uptake, such as the grade of the tumor, the impact of necrosis on BSGI examinations, and the cell type. Furthermore, additional ongoing studies are evaluating how BSGI impacts changes in patient management.

Limitations of the study include small sample size, single institution review, and retrospective design.

In summary, our study demonstrates the sensitivity of BSGI for the detection of DCIS (91%) was higher than that found with mammography (82%) and MRI (88%), and is a useful adjunct imaging modality for the detection of both clinically suspicious and occult foci of DCIS. (7).

ACKNOWLEDGMENTS

The authors would like to thank Joyce Raub, MS, for performing the BSGI studies and maintaining the patient database. The authors also are grateful for the statistical analysis performed by Shira Fishman, MS, and Kristen Dixon for assistance with manuscript revision.

REFERENCES

1. Jemal A, Murray T, Ward E, et al. Cancer statistics 2005. *CA Cancer J Clin* 2005; 55:10-30.
2. Burstein HJ, Polyak K, Wong JS, et al. Ductal carcinoma in situ of the breast. *N Engl J Med* 2004; 350:1430-1441.
3. Bluemke DA, Gatsonis CA, Chen MH, et al. Magnetic resonance imaging of the breast prior to biopsy. *JAMA* 2004; 292:2735-2742.
4. Hwang ES, Kinkel K, Esserman LJ, et al. Magnetic resonance imaging in patients diagnosed with ductal carcinoma-in-situ: value in the diagnosis of residual disease, occult invasion, and multicentricity. *Ann Surg Oncol* 2003; 10:381-388.
5. Orel SG, Mendonca MH, Reynolds C, et al. MR imaging of ductal carcinoma in situ. *Radiology* 1997; 202:413-420.
6. Taillefer R. Clinical applications of 99mTc-sestamibi scintimammography. *Semin Nucl Med* 2005; 35:100-115.
7. Schillaci O, Buscombe JR. Breast scintigraphy today: indications and limitations. *Eur J Nucl Med Mol Imaging* 2004; 31(Suppl 1):S35-S45.
8. Khalkhali I, Cutrone JA, Mena IG, et al. Scintimammography: the complementary role of Tc99m sestamibi prone breast imaging for the diagnosis of breast carcinoma. *Radiology* 1995; 196:421-426.
9. Khalkhali I, Villanueva-Meyer J, Edell SL, et al. Diagnostic accuracy of 99m Tc-Sestamibi breast imaging: multicenter trial results. *J Nucl Med* 2000; 41:1973-1979.
10. Papantoniou V, Tsiouris S, Maita E, et al. Imaging in situ breast carcinoma (with or without an invasive component) with technetium-99m 20methoxy isobutyl isonitrile scintimammography. *Breast Cancer Res* 2005; 7:R33-R45.
11. Ikeda DM, Birdwell RL, Daniel BL. Potential role of magnetic resonance imaging and other modalities in ductal carcinoma in situ detection. *MRI Clin N Am* 2001; 9:345-356.

© 2007