

# Breast-Specific Gamma Imaging with $^{99m}\text{Tc}$ -Sestamibi and Magnetic Resonance Imaging in the Diagnosis of Breast Cancer—A Comparative Study

Rachel F. Brem, MD,\* Ivan Petrovitch, MD,\* Jocelyn A. Rapelyea, MD,\* Heather Young, PhD,<sup>†</sup> Christine Teal, MD,<sup>‡</sup> and Tricia Kelly, MD<sup>‡</sup>

\**Breast Imaging and Intervention, Department of Radiology, <sup>†</sup>Biostatistics, School of Public Health and Health Sciences, and <sup>‡</sup>Breast Care Center, Department of Surgery, The George Washington University, Washington, D.C.*

■ **Abstract:** The purpose of this study was to compare the sensitivity and specificity of breast-specific gamma imaging (BSGI) using a high-resolution breast-specific gamma camera and magnetic resonance imaging (MRI) in patients with indeterminate breast findings. Twenty-three women with an indeterminate breast finding that required BSGI and MRI as deemed necessary by the interpreting radiologist or referring physician were included. MRI was performed on a GE 1.5T scanner and BSGI was performed on a Dilon high-resolution breast-specific gamma camera. All imaging findings were correlated with pathologic diagnosis. Thirty-three indeterminate lesions were evaluated in the study. There were a total of nine pathologically confirmed cancers. There was no statistically significant difference in sensitivity of cancer detection between BSGI and MRI. BSGI demonstrated a greater specificity than MRI, 71% and 25%, respectively. BSGI has equal sensitivity and greater specificity than MRI for the detection of breast cancer. ■

**Key Words:** breast cancer, molecular imaging, MRI

Mammography has been shown to be effective in screening women for breast cancer with a resultant decrease in mortality (1). However, mammography is an imperfect examination with a sensitivity of 85% that decreases to 68% in patients with dense breast tissue with a specificity of 20–30% (2). Therefore, adjunct imaging modalities are being developed and increasingly utilized to improve breast cancer diagnosis.

Magnetic resonance imaging (MRI) has been shown to provide an effective imaging adjunct for the diagnosis of breast cancer. MRI provides a morphologic as well as physiologic approach to evaluating the breast. The sensitivity and specificity of MRI in detecting breast cancer ranges from 88–99% to 37–83%, respectively (3–7). While MRI has been lauded for its high sensitivity it has also been critiqued for its widely variable specificity.

Breast-specific gamma imaging (BSGI) is a physiologic approach to breast imaging using a high-resolution gamma camera and Tc-Sestamibi. Previous work has examined the utility of scintimammography utilizing a conventional planar gamma camera as an adjunct imaging modality for breast cancer diagnosis (8–10). However, conventional gamma cameras are limited in their ability to image the breast due to excessive organ-to-detector distance as well as difficulty in detecting subcentimeter lesions and the ability to image in positions comparable to mammography (11). Recent advances in technology have resulted in the development of high-resolution gamma cameras specifically tailored to image the breast (11–13). Previous work has demonstrated high-resolution cameras to be superior to conventional gamma imaging in both detecting cancer as well as in screening high-risk patients (11,12,14,15). This type of breast imaging which utilizes a high-resolution gamma camera is referred to as BSGI.

With the advent of high-resolution gamma cameras further studies of BSGI versus MRI is warranted as both are physiologically based adjunct

Address correspondence and reprint requests to: Rachel F. Brem, MD, 2150 Pennsylvania Ave, NW, Washington, DC 20037, USA, or e-mail: rbrem@mfa.gwu.edu.

imaging modalities for the diagnosis of breast cancer.

The purpose of this study was to compare the sensitivity and specificity of BSGI using a high-resolution breast-specific gamma camera and MRI in patients with indeterminate breast findings.

## MATERIALS AND METHODS

This study was approved by our institutional review board. All patients enrolled in the study presented with an indeterminate breast finding that required BSGI and MRI as part of their clinical workup as determined by their clinicians. These patients subsequently went on to biopsy, or if a lesion for which MRI-guided biopsy was recommended, and was not seen at the time the patient presented for biopsy, then the patient went on to have a short interval follow-up with MRI. Patients were scheduled to receive both a dynamic contrast-enhanced MRI of the abnormal breast and a BSGI study of both breasts in no particular order. The patients had both studies performed within 0–42 days, (mean = 12 days).

Breast-specific gamma imaging examinations were performed using 25.0–30.0 mCi of  $^{99m}\text{Tc}$ -sestamibi (925–1110 MBq) (Miraluma; DuPont Pharma, Billerica, MA) administered through an antecubital vein. Within 10 minutes, images were obtained in the cranial caudal and medial lateral oblique projections using a high-resolution breast-specific gamma camera (Dilon 6800; Dilon Technologies, Inc., Newport News, VA). Additional images were obtained as deemed necessary for clinical evaluation by the interpreting radiologist.

Magnetic resonance imaging was performed using a GE 1.5-T system (GE Healthcare, Milwaukee, WI) using a dedicated breast coil. An initial 3D localizing sequence was performed followed by sagittal  $T_1$  with fat saturation (repetition time millisecond/echo time millisecond 525/12–24),  $T_2$  with fat saturation (6000/85), and axial  $T_2$  (6000/85) fat-saturated sequences. After administration of 33 ml of gadopentate-dimeglumine (Magnevist, Berlex, Germany) 3D volumetric dynamic images were obtained at 70-second intervals for a total of five cycles followed by a sagittal  $T_1$  (6.3/2.9–12) fat-saturated postcontrast sequence.

Breast-specific gamma imaging and MR images were interpreted by two experienced breast imagers. The patients' clinical history was made available at the time of image review.

Breast-specific gamma imaging examinations were interpreted as normal (score of 1), with no focal or diffuse uptake; benign (score of 2), with minimal patchy uptake; probably benign (score of 3), with scattered patchy uptake; probably abnormal (score of 4), with mild focal uptake; and abnormal (score of 5), with marked focal radiotracer uptake. All studies were classified as positive or negative. A study was classified as negative if it was categorized as 1, 2, or 3 and positive if it was classified as 4 or 5. MRI was interpreted using a BI-RADS classification system. Patients with a BI-RADS 1, 2, or 3 interpretations were defined as negative, and patients with a BI-RADS 4 or 5 interpretations were defined as positive studies.

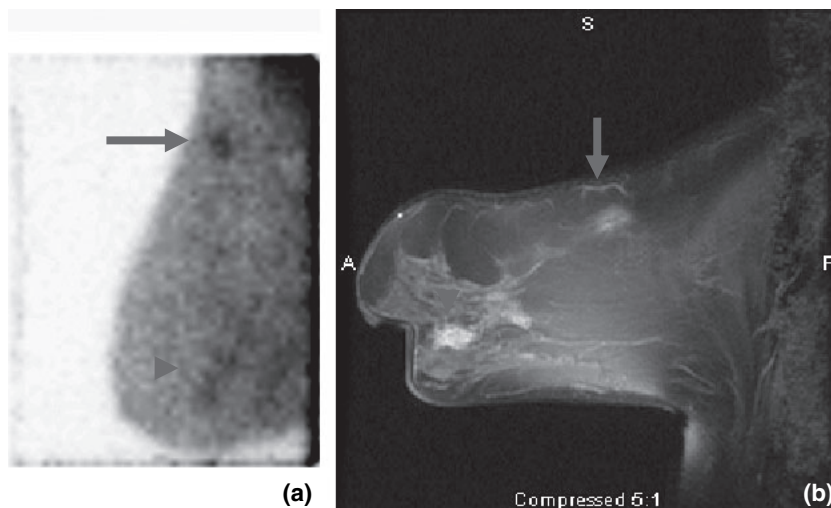
Abnormal foci of enhancement on MRI images as well as areas of abnormal increased radiotracer uptake were correlated with the pathologic findings. Lesions were considered to be the same with BSGI and MRI if they were in the same quadrant and the same distance from the nipple. In the event of a diagnosis of cancer, the histopathologic type of cancer and size of the tumor was recorded. In patients with invasive cancer with ductal carcinoma in situ (DCIS), the measurement of the invasive component was used.

Sensitivity, specificity, positive, and negative predictive values were calculated for both BSGI and MRI. Comparison of these values was performed by calculating the 95% confidence interval for each parameter. Statistical significance was determined by comparing the confidence interval of each parameter for BSGI with MRI. A value was considered statistically significant if the CI did not overlap between the two imaging modalities.

## RESULTS

Twenty-three women, (age ranging from 33 to 70 years, mean  $53 \pm 10$  years) with 33 indeterminate lesions were included. There were a total of nine pathologically confirmed cancers in eight patients. One patient had two separate foci of cancer in different quadrants of the breast (Fig. 1). There were four DCIS, three infiltrating ductal carcinomas, one invasive lobular carcinoma, and one infiltrating carcinoma with duct and lobular features. In the patient with two foci of cancer, one lesion demonstrated DCIS while the other lesion demonstrated infiltrating ductal carcinoma. The size and type of these lesions is listed in Table 1.

**Figure 1.** A 69-year-old female with new amorphous calcifications in the retroareolar left breast and a positive history of breast cancer. (a) Breast-specific gamma imaging demonstrates focal increased radiotracer uptake in the superior (arrow) and inferior (arrowhead) portions of the breast. (b) Post-contrast T<sub>1</sub> fat-saturated magnetic resonance imaging demonstrates an abnormal area of enhancement in the superior (arrow) and inferior portions (arrowhead) of the breast. The superior lesion is an infiltrating ductal carcinoma, 8 mm (arrow), while the inferior lesion is a ductal carcinoma in situ, 20 mm (arrowhead).



**Table 1. Pathology and Size of Cancers**

Patient	Cancer type	Size (largest diameter)
1	Infiltrating ductal carcinoma	Size not available
2	Invasive lobular carcinoma	22 mm
3	Ductal carcinoma in situ	24 mm
4	Infiltrating ductal carcinoma	13 mm
5	Ductal carcinoma in situ	Extensive and multifocal
6a	Infiltrating ductal carcinoma	8 mm
6b	Ductal carcinoma in situ	20 mm
7	Infiltrating carcinoma	50 mm
8	Ductal carcinoma in situ	23 mm

There were seven false-positive BSGI studies. At biopsy, six demonstrated fibrocystic changes, and one was a subclinical abscess following trans-rectus abdominis myocutaneous (TRAM) reconstruction (Fig. 2).

There was a single false-negative BSGI. The pathologic diagnosis obtained by core needle biopsy was poorly differentiated infiltrating ductal carcinoma.

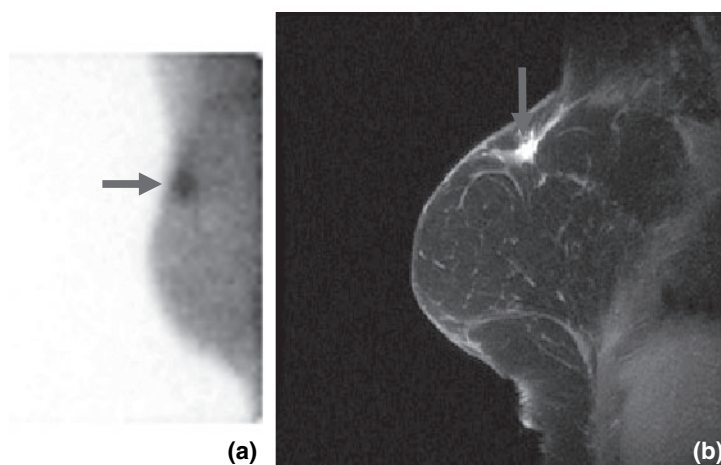
**Table 2. Pathology of MRI False Positives**

Histopathologic diagnosis	No. cases (%)
Fibrocystic changes	11/18 (61)
Lobular neoplasia	4/18 (22)
Abscess	1/18 (6)
Fibrosis with foreign body giant cells	1/18 (6)
Repeat examination negative	1/18 (6)

MRI, magnetic resonance imaging.

Magnetic resonance imaging demonstrated 18 false-positive lesions (Table 2). Pathologic examination demonstrated fibrocystic changes in 11, lobular neoplasia in four, fibrosis with foreign body giant cell reaction in one, and abscess in one. One patient returned for MR-guided biopsy of a previously visualized lesion. MRI at the time of scheduled biopsy did not demonstrate an abnormality. The biopsy was cancelled and repeat MRI examination in 3 months

**Figure 2.** A 44-year-old female with a history of prior right mastectomy and TRAM reconstruction presented with increasing calcifications. (a) Breast-specific gamma imaging demonstrates a focal area of increased radiotracer uptake in the superior portion of the breast. (b) Postcontrast T<sub>1</sub> fat-saturated magnetic resonance imaging demonstrates a focal spiculated area of enhancement in the superior portion of the breast. At biopsy, pathology demonstrates a focal abscess.



**Table 3. Sensitivity, Specificity, PPV, and NPV of BSGI and MRI**

	Sensitivity NS	Specificity S	PPV NS	NPV NS
Breast-specific gamma imaging	89 (51–99)	71 (49–87)	53 (27–78)	94 (71–100)
Magnetic resonance imaging	100 (63–100)	25 (11–47)	33 (17–54)	100 (52–100)

95% Confidence intervals are listed in parenthesis after each value. PPV, positive predictive value; NPV, negative predictive value; BSGI, breast-specific gamma imaging; MRI, magnetic resonance imaging; NS, not statistically significant.

demonstrated no lesion. This patient was considered negative.

In this study, there were no false-negative MRI examinations. Four nonmalignant lesions demonstrated positive findings at both MRI and BSGI. Of these four, two were lobular neoplasia and two were fibrocystic changes. Sensitivity, specificity, positive predictive value, and negative predictive values were calculated for both BSGI and MRI (Table 3).

## DISCUSSION

This study was designed to compare BSGI with MRI in patients with equivocal breast findings. BSGI yields a comparable sensitivity to MRI while providing a much higher degree of specificity. The specificity of BSGI of 71% was statistically significantly higher than that for MRI (25%). The sensitivity of BSGI and MRI demonstrated no statistically significant difference.

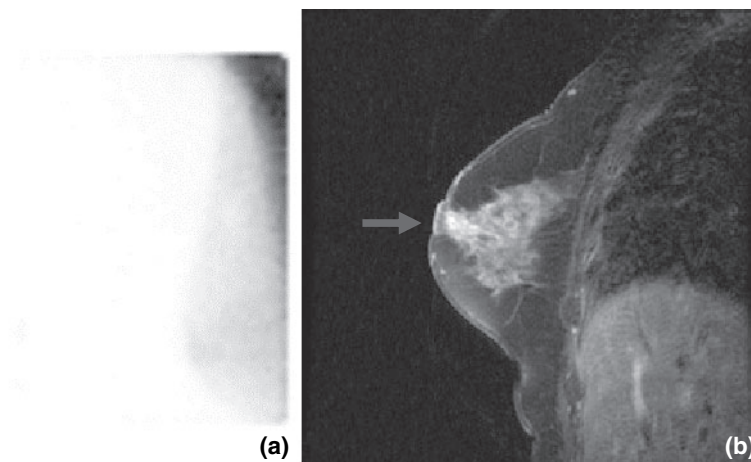
There have been several studies comparing scintimammography utilizing a conventional gamma camera with MRI. A common issue in these studies is the limited intrinsic spatial resolution when using a

conventional gamma camera where cancers less than 1 cm cannot be reliably seen (16,17). In our study, the smallest cancer detected measured 3 mm. The advent of the high-resolution breast-specific gamma camera has been shown to improve the ability to image sub-centimeter cancers (11,14).

In four cases of lobular neoplasia, two demonstrated false positives with both MRI and BSGI and in the other two MRI demonstrated false-positive results with a normal BSGI (Fig. 3). These high-risk lesions are considered more metabolically active and therefore have increased uptake of both  $^{99m}\text{Tc}$ -sestamibi and gadolinium. Although lobular neoplasia is not malignant, these two physiologic studies accurately demonstrate the increased metabolic activity of lobular neoplasia and may suggest that BSGI is more specific for breast cancer.

There was only one false negative with BSGI. The cancer was an infiltrating ductal carcinoma, poorly differentiated. The tumor was in the posteroinferior portion of the breast. It is possible that the lesion was not visualized due to its location and suboptimal positioning. Alternatively, it is possible that this poorly differentiated cancer did not have an affinity for  $^{99m}\text{Tc}$ -sestamibi. Additional studies are needed to further define the mechanism of affinity of breast cancer for  $^{99m}\text{Tc}$ -sestamibi.

The 100% sensitivity and 27% specificity of MRI in our study is likely due to the small number of cancers. Other studies with larger populations have reported a lower sensitivity and greater specificity. Therefore, additional studies with greater numbers of patients and cancers are needed to further compare the sensitivity and specificity of BSGI and MRI.



**Figure 3.** A 68-year-old female with history of lobular neoplasia. (a) Breast-specific gamma imaging demonstrates no abnormal foci of radiotracer uptake. (b) Magnetic resonance imaging demonstrates an abnormal area of enhancement in the retroareolar portion of the breast. The pathology demonstrates lobular neoplasia.

This study was not designed to compare the ease of performing and interpreting BSGI versus MRI examinations. Nevertheless, it is noteworthy that an MRI examination generates several hundred images whereas a BSGI study generates four to eight images for review. The time to interpret these two types of studies is reflected by the number of images obtained. Further investigation of the radiologist interpretation time for each examination would be beneficial. However, at our institution, interpretation time of BSGI examinations is less than that for MRI examinations.

Patient comfort during an examination is an important consideration. BSGI examinations are performed with the patient sitting upright with no breast compression compared to the MRI examination where the patient is in an MRI scanner where claustrophobia is not an uncommon issue. This demonstrates yet additional advantages of BSGI over MRI, which requires additional investigation to quantify.

### CONCLUSION

This study demonstrates that BSGI has an equal sensitivity with a higher specificity than MRI as an adjunct imaging modality for the diagnosis of breast cancer. Additional advantages include greater ease of imaging for the patient, lower cost, and far fewer images likely resulting in more rapid interpretation time for the radiologist, although additional studies to quantify these factors are needed. Larger, multi-institutional studies are needed to further compare breast MRI and BSGI.

### Acknowledgments

We would like to acknowledge Joyce Raub, RT, BA, MA who assisted in the preparation of this manuscript.

### REFERENCES

- Berry DA, Cronin KA, Plevritis SK, *et al.* Effect of screening and adjuvant therapy on mortality from breast cancer. *N Engl J Med* 2005;353:1784–92.
- Rosenberg RD, Hunt WC, Williamson MR, *et al.* Effects of age, breast density, ethnicity, and estrogen replacement therapy on screening mammographic sensitivity and cancer stage at diagnosis: review of 183,134 screening mammograms in Albuquerque, New Mexico. *Radiology* 1998;209:511–18.
- Bluemke DA, Gatsonis CA, Chen MH, *et al.* Magnetic resonance imaging of the breast prior to biopsy. *JAMA* 2004;292:2735–42.
- Drew PJ, Turnbull LW, Chatterjee S, *et al.* Prospective comparison of standard triple assessment and dynamic magnetic resonance imaging of the breast for the evaluation of symptomatic breast lesions. *Ann Surg* 1999;230:680–85.
- Fischer U, Kopka L, Grabbe E. Breast carcinoma: effect of preoperative contrast-enhanced MR imaging on the therapeutic approach. *Radiology* 1999;213:881–88.
- Kuhl CK, Mielcareck P, Klaschik S, *et al.* Dynamic breast MR imaging: are signal intensity time course data useful for differential diagnosis of enhancing lesions? *Radiology* 1999;211:101–10.
- Teifke A, Hlawatsch A, Beier T, *et al.* Undetected malignancies of the breast: dynamic contrast-enhanced MR imaging at 1.0 T. *Radiology* 2002;224:881–88.
- Imbriaco M, Del Vecchio S, Riccardi A, *et al.* Scintimammography with <sup>99m</sup>Tc-MIBI versus dynamic MRI for non-invasive characterization of breast masses. *Eur J Nucl Med* 2001;28:56–63.
- Tiling R, Khalkhali I, Sommer H, *et al.* Role of technetium-<sup>99m</sup> sestamibi scintimammography and contrast-enhanced magnetic resonance imaging for the evaluation of indeterminate mammograms. *Eur J Nucl Med* 1997;24:1221–29.
- Polan RL, Klein BD, Richman RH. Scintimammography in patients with minimal mammographic or clinical findings. *Radiographics* 2001;21:641–53.
- Brem RF, Schoonjans JM, Kieper DA, Majewski S, Goodman S, Civelek C. High-resolution scintimammography: a pilot study. *J Nucl Med* 2002;43:909–15.
- Scopinaro F, Pani R, De Vincentis G, Soluri A, Pellegrini R, Porfiri LM. High-resolution scintimammography improves the accuracy of technetium-<sup>99m</sup> methoxyisobutylisonitrile scintimammography: use of a new dedicated gamma camera. *Eur J Nucl Med* 1999;26:1279–88.
- Mueller B, O'Connor MK, Blevis I, *et al.* Evaluation of a small cadmium zinc telluride detector for scintimammography. *J Nucl Med* 2003;44:602–09.
- Coover LR, Caravaglia G, Kuhn P. Scintimammography with dedicated breast camera detects and localizes occult carcinoma. *J Nucl Med* 2004;45:553–58.
- Brem RF, Rapelyea JA, Zisman G, *et al.* Occult breast cancer: scintimammography with high-resolution breast-specific gamma camera in women at high risk for breast cancer. *Radiology* 2005;237:274–80.
- Bagni B, Franceschetto A, Casolo A, *et al.* Scintimammography with <sup>99m</sup>Tc-MIBI and magnetic resonance imaging in the evaluation of breast cancer. *Eur J Nucl Med Mol Imaging* 2003;30:1383–88.
- Bone B, Wiberg MK, Szabo BK, Szakos A, Danielsson R. Comparison of <sup>99m</sup>Tc-sestamibi scintimammography and dynamic MR imaging as adjuncts to mammography in the diagnosis of breast cancer. *Acta Radiol* 2003;44:28–34.